



## Research Article

# JOURNAL OF APPLIED PHARMACEUTICAL RESEARCH | JOAPR

www.japtronline.com

ISSN: 2348 – 0335

## EVALUATION OF WOUND HEALING EFFECT OF COLOSTRUM AND CURCUMIN CREAM IN RAT EXCISION WOUND MODEL

Aakash R, Sakthibalan M\*, Mangaiarkkarasi A, Prasad C

### Article Information

Received: 16<sup>th</sup> August 2021

Revised: 4<sup>th</sup> December 2021

Accepted: 10<sup>th</sup> January 2022

Published: 31<sup>st</sup> March 2022

### Keywords

Wound healing, Colostrum,  
 Curcumin, Povidone iodine

### ABSTRACT

**Background:** Proper wound healing is very crucial for the reconstruction of injured tissues. Compared to the conventional dressings, currently there are many novel biological wound dressings and healing agents containing colostrum which has many advantages. **Aim & Objective:** This experimental study was done to evaluate the effect of colostrum and curcumin cream dressing and compare it with that of conventional Povidone iodine dressing. **Methods:** The rats were anesthetized and excision wounds were created. Wounds were then measured with a standard measuring scale on the day of wounding and then subsequently at a time interval of 4 days till day 20, then on alternate days. After tracing the wound area was treated with the Test and Standard drugs on Day 1,4,8,12,16 and 20. The data was then analysed using Chi square, one-way ANOVA and two tailed t test using Graph pad prism software version 5.0. **Results:** Efficacy of Colostrum 10% & Curcumin 1% cream (test) was equal to that of povidone iodine 10% (standard) cream with respect to wound contraction and wound healing. But, with respect to the rate of wound healing, Colostrum 10% & Curcumin 1% cream treated group was better compared to the povidone iodine 10% cream treated group. **Conclusion:** Colostrum plus Curcumin cream has shown a better wound healing at a short time span in excisional wound model in rats, when compared to the conventional povidone iodine cream. Thus, the Colostrum plus curcumin cream appear to be an economical and safe alternative to costly therapies like growth factors for wound healing

### INTRODUCTION

Wounds are physical injuries, which results in a breach or break in the skin layers. Proper wound healing is very crucial for the reconstruction of the anatomical stability and altered functional status of the skin. Healing of injured tissues usually happens in

a sequential manner, which includes inflammatory reactions, proliferation of tissue and cellular migration [1]. The various stages of inflammation usually begins soon after an injury, followed by vasoconstriction which leads to homeostasis and also releases many inflammatory mediators. In the process of

\* Sri Venkateshwaraa Medical College Hospital and Research Centre, Pondicherry, India

**\*For Correspondence:** saheerose@gmail.com

©2022 The authors

This is an Open Access article distributed under the terms of the Creative Commons Attribution (CC BY NC), which permits unrestricted use, distribution, and reproduction in any medium, as long as the original authors and source are cited. No permission is required from the authors or the publishers. (<https://creativecommons.org/licenses/by-nc/4.0/>)

wound healing, proliferation of tissues which is characterized by formation of granulation tissue with fibroblast and angiogenesis plays a vital role. This is followed by collagen formation which helps in tissue remodelling and increases the tensile strength of the healing wound [2].

There are various factors like poor tissue perfusion, excess free radical generation, oxidative stress, repeated trauma, infection and excess inflammation which contributes to delayed wound healing and prolongation of wound chronicity [3,4]. Currently there are many novel biological wound dressings and healing agents containing Collagen and colostrum, which gives a more physiological interface between the wound and the environment and thereby making it impermeable for bacterial growth and promotes wound healing.

Bovine Colostrum with curcumin, which is available in a cream formulation, consists of many growth factors, responsible for growth of cells and healthy regeneration of tissues of the skin and muscle [5]. Colostrum with curcumin cream dressing has many advantages over the conventional wound dressing, which includes formation of healthy granulation tissue, well established antiseptic property of Curcumin, reduction in inflammatory cells and its mediators which can result in rapid wound healing process with less complications[6,7]. Colostrum contains epithelial/epidermal growth factor (EGF) for tissue repair and regeneration. It also consists of Insulin like growth factor (IGF-1) and fibroblast growth factor (FGF) that helps in a healthier and rapid wound healing process [6, 7, 8]. Each gram of our test product (cream) contains Cow Colostrum 10% and Curcumin 1%.

Hence, this study was conducted to evaluate the effect of colostrum and curcumin cream dressing and compare it with that of conventional Povidone iodine dressing in the management of deep excision wounds in albino wistar rats.

### **MATERIALS AND METHODS**

The study was conducted from December 2020 to May 2021 after getting approval from Institutional Animal Ethics Committee (Ref. No.1/IAEC/SVMC/8/2020), with the objective to evaluate the effect of colostrum and curcumin cream dressing and compare it with that of conventional Povidone iodine dressing.

### **ANIMALS:**

Eighteen Swiss Albino Wistar rats (180–250 gm) of male sex of age 6 months to 1 year, were obtained from animal house of our institution. They were kept at 24°C and relative humidity 44–56%, light and dark cycles of 12 h, for one week before and during the experiments. Animals were provided with standard pellet diet and water *ad libitum*. All experiments were performed according to CPCSEA guidelines.

### **TEST PRODUCT PREPARATION:**

#### **Preparation of Aqueous phase:**

Add allantoin + Polysorbate 80 + Purified water in main vessel mix slowly to dissolve and heat to 75 to 80 degree Celsius.

#### **Preparation of Oil Phase:**

Add Cetostearyl alcohol + Glyceryl monostearate + Cetyl alcohol in separate vessel and heat to melt at 75 to 80 degree Celsius.

#### **Preparation of Gel phase:**

Add purified water to separate vessel then dissolve Disodium EDTA in it. Then add Carbopol slowly to form dispersion without any lumps. Add small quantity to Sodium Hydroxide to form gel

#### **Preparation of Curcumin solution:**

Add Propylene glycol in separate vessel and then add curcumin extract into it and mix to dissolve if required heat the mixture up to 35 degrees.

Note: Don not heat mixture above 40 degree Celsius.

#### **Preparation of Cream:**

1. Transfer oil phase to aqueous phase & homogenize for 5-10 minutes.
2. Stop homogenization and mix with anchor and add Colostrum at 50°Celsius and mix at high speed make sure no colostrum lumps are present in the cream.

Dermal / In vitro Toxicity studies on the test product are planned in future, for further evaluation.

### **PROCEDURE**

Eighteen rats were divided into 3 groups with 6 in each.

Group 1: Control – Normal saline dressing.

Group 2: Standard - Povidone iodine 10% dressing.

Group 3: Test – Colostrum 10% & Curcumin 1% cream dressing

The rat were anesthetized with ketamine (30 mg/kg, ip) and an area of about  $\approx 1$  cm<sup>2</sup> was marked on the back of the rat after trimming the hair. Full thickness of the marked skin area was

then cut of carefully under anaesthesia. Wounds were then traced with graph paper and measured with a standard measuring scale on the day of wounding and then subsequently at a time interval of 4 days till day 20, then on alternate days until complete healing is achieved.

After tracing the wound area was treated with the Test and Standard drugs (sufficient quantity of around 200 cu.mm, to completely fill the wound area of 1 cm<sup>2</sup>) and it was covered with a barrier dressing (as per the respective treatment groups) on Day 1,4,8,12,16 and 20. Variations in wound area were measured periodically and the rate of wound contraction was also calculated. The data was then analysed using Chi square, one-way ANOVA and two tailed t test using Graph pad prism software version 5.0. Significance in wound healing of the test group (Colostrum 10% & Curcumin 1% cream) is derived by comparing healed wound area on respective days with healed wound area of control group (untreated group) and standard group (povidone iodine dressing) [9,10].

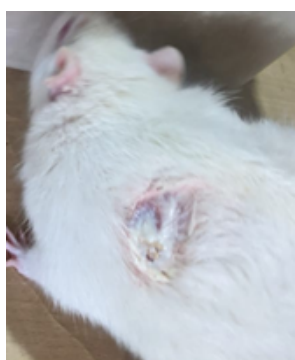

Fig.1. Test Group

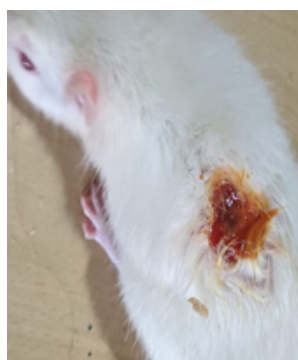


Fig 2. Standard Group

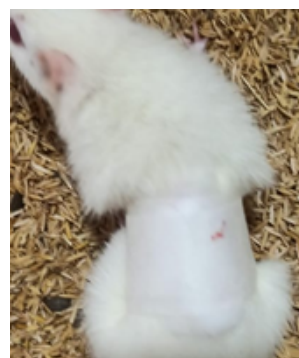

Fig.3. Barrier dressing applied

The outcome parameters assessed were as follows:

- 1) The percentage of wound contraction, wound area and period of epithelialization, that is, day of fall of eschar was assessed.

$$\% \text{ wound contraction} = \left( \frac{\text{Healed area}^0}{\text{Total wound area}} \right) \times 100$$

(°Healed area = original wound area – present wound area)

- 2) The meantime taken for complete healing was assessed and compared between the groups.
- 3) Any signs of infections and allergic reactions were also documented among the different groups during the study period.

### STATISTICS

The mean ± SD values of variables like wound size, wound contraction percentage and time taken for healing, was calculated for each group. The data was analysed using Chi square, one-way ANOVA and two tailed t test, using Graph pad prism software version 5.0. p<0.05 was considered to be statistically significant.

### RESULTS

**Table 1: Percentage of wound contraction: (N=6 in each group):**

DAY	Control	Test (Colostrum 10% & Curcumin 1%)	Standard (Povidone iodine 10%)	P value*
Day 4	25.073	30.15404	28.01645	0.850
Day 8	41.3966	51.75956	42.70991	0.730
Day 12	64.08588	83.25397	79.63719	0.470
Day 16	74.01323	96.2963	90.74074	0.298
Day 20	98.66667	100	99.66667	0.785

\*Data was analysed using Chi square test. There was no statistically significant improvement in the percentage of wound contraction between the control, test and standard group. But, there was a better wound contraction Percentage wise, in the standard and test group, which was more marked in the test group.

**Table 2: Wound size: (Mean  $\pm$  SD) in sq.cm. (N=6 in each group):**

DAY	Control	Test (Colostrum 10% & Curcumin 1%)	Standard (Povidone iodine 10%)	P value
Day 1	1.07 $\pm$ 0.15	1.08 $\pm$ 0.13	1.08 $\pm$ 0.14	0.988
Day 4	0.79 $\pm$ 0.1	0.74 $\pm$ 0.2	0.78 $\pm$ 0.14	0.8362
Day 8	0.47 $\pm$ 0.11	0.38 $\pm$ 0.18	0.45 $\pm$ 0.13	0.5338
Day 12	0.17 $\pm$ 0.11	0.05 $\pm$ 0.02	0.09 $\pm$ 0.02	0.0191*
Day 16	0.04 $\pm$ 0.01	0.003 $\pm$ 0.002	0.008 $\pm$ 0.009	0.0001*
Day 20	0.007 $\pm$ 0.005	0	0.002 $\pm$ 0.004	0.0143*

\*The data was analysed using one way ANOVA. It was found that there was a statistically significant improvement ( $p < 0.01$ ) in the wound size in both the Test and Standard group when compared with control on day 12, 16 and 20. There was a better and rapid wound healing in the Test group when compared to control group. Complete healing was achieved in the Test group by day 20.

**Table 3: Mean time for complete healing (Day of fall of Eschar):**

Mean	Control	Test (Colostrum 10% & Curcumin 1%)	Standard (Povidone iodine 10%)
Time duration	23 $\pm$ 2.7 days	18 $\pm$ 1.5 days	20 $\pm$ 2.4 days
P value		0.0027*	0.06*

\*Data was analysed using two tailed t test. The mean time taken for complete healing of wound, was statistically significant in the Test drug treated group when compared to Control. There was no significant difference between the test & standard group.

**Table 4: Images depicting the rate of wound healing on day 4, day 8, day 16 and day 20.**





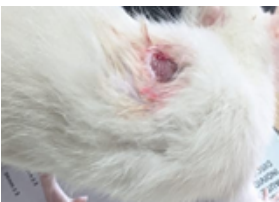
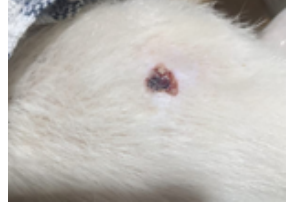


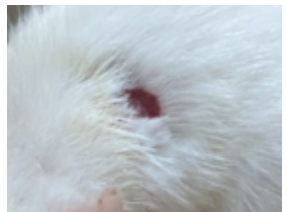



DAY	Control	Test (Colostrum 10% & Curcumin 1%)	Standard (Povidone iodine 10%)
Day 1			
Day 4			
Day 8			
Day 16			

Table 4 depicts the pictorial representation of the wound healing (photographs) from day 1 to day 20. The test drug treated group shows a better improvement by day 18 to 20 similar to that of the standard group.



The results of this study displays that the efficacy of Colostrum 10% & Curcumin 1% cream (test) was equal to that of povidone iodine 10% (standard) cream with respect to wound contraction and wound healing (table 1 and 2). But, with respect to the rate of wound healing (time taken for complete healing-fall of Eschar), Colostrum 10% & Curcumin 1% cream treated group was better compared to the povidone iodine 10% cream treated group when compared with that of the Control group (table 3). The photographic improvement as shown in table 4 also confirms the same. There were no signs of infections or allergic reactions during the study period among the different treatment groups.

### **DISCUSSION**

It is evident from our study that the Colostrum plus curcumin cream dressing was equally effective to the conventional povidone iodine dressing with respect to wound contraction and better than the povidone iodine with respect to time taken for complete healing. Colostrum cream produced a rapid healing response compared to the standard povidone iodine dressing.

Literature evidence shows that Colostrum consists of Platelet derived growth factors, lactoferrin and stem cells which help in wound healing process and the same has been confirmed in present study. It was observed in previous studies that Colostrum led to increase in collagen content of wound, tensile strength of wound and acceleration of epithelialization. Previous study shows that on treatment with colostrum, the wound was predominant with fibroblasts and new blood vessels and a more systematic arrangement of collagen fibres in two weeks' time with reported early wound healing [8,9]. Thus, Colostrum due to the presence of lactoferrin or stem cells may be effectively used in the management of wounds of different aetiologies.

Colostrum growth factors also play a vital role of keeping the intestinal mucosa sealed and impermeable to toxins. This is evidenced by colostrum's ability to control chronic diarrhoea caused by gut inflammation related to dysbiosis. In another study, milk fat globule factor 8 plays an important role in maintaining intestinal homeostasis and promotion of mucosal healing and suggest that colostrum can also be beneficial for the treatment of bowel injuries [10,11,12].

Sporn et al., has reported that various growth factors were isolated from Bovine Colostrum like the Epithelial Growth Factor and Transforming Growth Factors (TGF A & B) which

helps in the process of Wound Healing. Our study has also shown that colostrum is very much effective in promoting wound healing at a rapid phase, when it is applied topically to the affected site [13]. Research done by Bhora et al., has confirmed the same, that these growth factors were responsible for the wound healing process [14].

Noda et al., has also reported that TGF A & B present in bovine colostrum was helpful in tissue proliferation and repair and in embryonic development. They have also reported, that Colostrum promotes synthesis and repair of DNA [15].

In another study combination of milk colostrum and honey when topically applied showed anti-microbial activity. Our novel combination of Colostrum with Curcumin may also have similar antimicrobial property, as Curcumin is a well-established anti-microbial agent [16]. Thus, the dual action of Colostrum and Curcumin produces an effective and rapid wound healing process without any allergic reactions or any complications due to infections. Colostrum is also a cheap alternative to many growth factors which are employed in wound healing process.

### **CONCLUSION**

Colostrum plus Curcumin cream has shown a better wound healing at a short time span in excisional wound model in rats, when compared to the conventional povidone iodine cream. Thus, the Colostrum plus curcumin cream appear to be an economical and safe alternative to costly therapies like growth factors for wound healing. Further human trials can be planned to evaluate its clinical efficacy in wound healing.

### **FINANCIAL ASSISTANCE**

ICMR (Indian Council of Medical Research) STS

### **CONFLICT OF INTEREST**

The authors declare no conflict of interest

### **ACKNOWLEDGEMENT**

We thank our Institute (Sri Venkateshwaraa Medical College Hospital and Research Centre) for their support in conducting the study and Mr. S. Murali, President, Operations of Hilson Health for supplying us the samples of the Test product (Colostrum plus Curcumin Cream) at free of cost.

### **AUTHOR CONTRIBUTION**

Sakthibalan M, Mangaiarkarasi A and Aakash R designed the research work and made necessary corrections and revisions in the manuscript. Aakash R and Prasad C collected the data and

did a literature review and also contributed in preparing the manuscript. All the authors contribute from their expertise and framed the final manuscript.

## REFERENCES

- [1] Sidhu GS, Mani H, Gaddipati JP, Singh AK, Seth P, Banaudha KK, Patnaik GK, Maheshwari RK. Curcumin enhances wound healing in streptozotocin induced diabetic rats and genetically diabetic mice. *Wound Repair Regen.*, **7(5)**, 362-74 (1999)
- [2] Varoglu E, Seven B, Gumustekin K, Aktas O, Sahin A, Dane S. The effects of vitamin e and selenium on blood flow to experimental skin burns in rats using the <sup>133</sup>Xe clearance technique. *Central European Journal of Medicine* **5(2)**, 219–223 (2010)
- [3] Harding KG, Moore K and Phillips TJ. Wound chronicity and fibroblast senescence-implications for treatment. *International Wound Journal* **2(4)**:364–368 (2005)
- [4] Mikhal'chik EV, Anurov MV, Titkova SM, Miroshnikova EA, Lukasheva EV, Deeva IB, Ibragimova GA, Korkina LG. Activity of antioxidant enzymes in the skin during surgical wounds. *Bull Exp Biol Med.* **42(6)**, 667-9 (2006)
- [5] Singh O, Gupta SS, Soni M, Moses S, Shukla S, Mathur RK. Collagen dressing versus conventional dressing in chronic wounds: A retrospective study. *J Cutan Aesthet Sugery*, **4**, 12–16 (2011)
- [6] Gauthier SF, Pouliot Y, Maubois JL. Growth factors from bovine milk and colostrum: composition, extraction and biological activities. *Le Lait*, INRA Editions, **86(2)**, 99-125 (2006)
- [7] Kshirsagar AY, Vekariya MA, Gupta V, Pednekar AS, Mahna A, Patankar R, Shaikh A, Nagur B. A comparative study of colostrum dressing versus conventional dressing in deep wounds. *J Clin Diagn Res*, **9(4)**, 01-04 (2015)
- [8] Patil SU, Deshpande PK, Ghongane BB, Rane SR. Assessment of Healing Potential of Colostrum against Incisional Wound Model in Mice. *Int J Health Sci Res.*, **5(12)**, 197-203 (2015)
- [9] Patil SU, Deshpande PK, Ghongane BB. Comparative Wound Healing Potential of Topical Application of Phenytoin, Epidermal Growth Factor, Dimethyl Sulfoxide and Colostrum Against Excisional Wound Model in Mice. *Research Journal of Pharmaceutical, Biological and Chemical Sciences*, **6(5)**, 661-66 (2015)
- [10] Marchbank T, Playford RJ. Bovine colostrum or TGF $\beta$  (a major bioactive constituent of colostrum) were prophylactic against indomethacin induced injury. *Gut*, **42(suppl)**, A68 (abstr) (1998)
- [11] Bu HF, Zuo XL, Wang X, Ensslin MA, Koti V, Hsueh W, Raymond AS, Shur BD, Tan XD. Milk fat globule-EGF factor 8/lactadherin plays a crucial role in maintenance and repair of murine intestinal epithelium. *J Clin Invest.*, **117(12)**, 3673-83 (2007)
- [12] Playford RJ, Macdonald CE and Johnson WS. Colostrum and milk-derived peptide growth factors for the treatment of gastrointestinal disorders. *The American Journal of Clinical Nutrition*, **72(1)**, 5–14 (2000)
- [13] Sporn MB, Roberts AB, Shull JH, Smith JM, Ward JM, Sodek J. Polypeptide Transforming Growth Factors (TGF A & B) and Epithelial Growth Factor isolated from bovine colostrum used for wound healing in vivo. *Science*, **219**, 1329–31 (1983)
- [14] Bhora FY, Dunkin BJ, Batzri S, Aly HM, Bass BL, Sidawy AN, Harmon JW. Effect of growth factors on cell proliferation and epithelialization in human skin. *J Surg Res.*, **59(2)**, 236-44 (1995)
- [15] Noda K, Umeda M, Ono T. Transforming growth factor activity in human colostrum. *Gan.*, **75(2)**, 109-12 (1984)
- [16] Al-Jabri AA, Al Hosni SA, Nzeako B & Nsanze H. Antistaphylococcal activity of Omani honey in combination with bovine milk. *British Journal of Biomedical Science*, **62(2)**, 92-93 (2005)